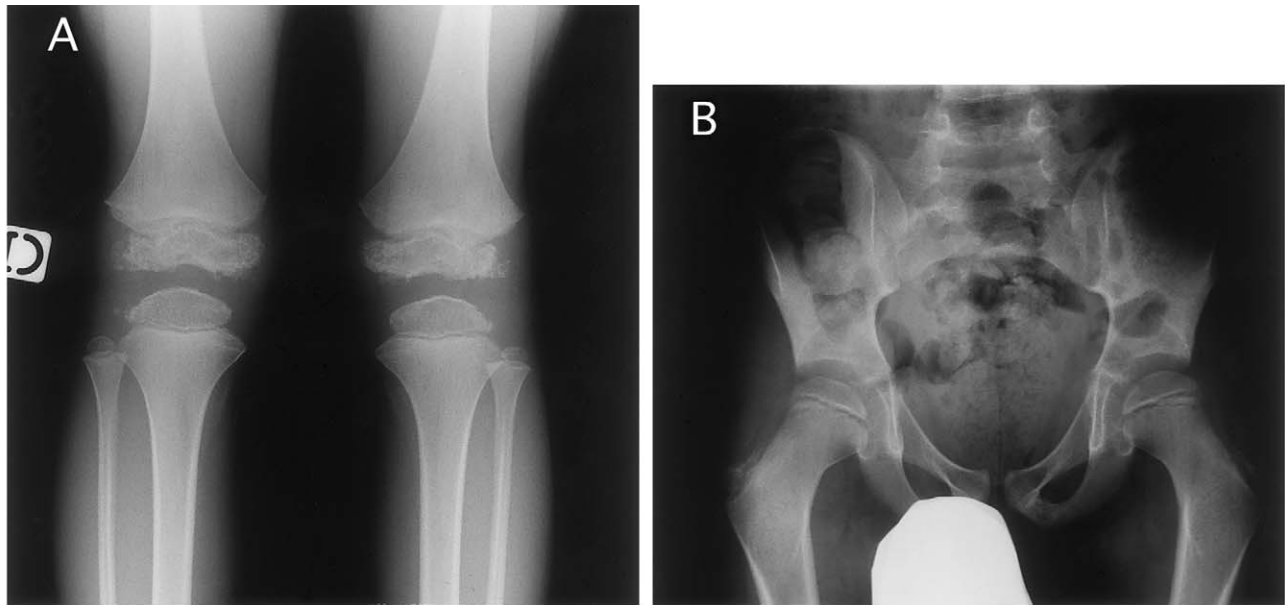


## Errata



In the April 1999 issue of the *Journal*, in “COL9A3: A Third Locus for Multiple Epiphyseal Dysplasia” (64: 1036–1044), by Paassilta et al., roentgenograms of the knees (fig. 2A) and pelvis (fig. 2B), on page 1040, were incorrectly identified in both the text and the figure legend. These films are not from subject IV-1 but from subject II-2 and were taken at age 59 years. Radiographs of the knees and pelvis of subject IV-1, taken at age 8 years, are shown in the figure below.